

## Histopathological findings of the liver and kidneys of wistar rat exposed to insect repellent



Ary Andini<sup>1\*</sup>, Lysa Veterini<sup>2</sup>, Edza Aria Wikurendra<sup>3</sup>, Achmad Syafruddin<sup>3</sup>,  
Defi Rimasari<sup>1</sup>, Munifa Nur Aida<sup>1</sup>

<sup>1</sup>Study Program of Medical Laboratory Technology, Faculty of Health, Universitas Nahdlatul Ulama Surabaya, Jl. Jemursari No 51-57 Surabaya, East Java, Indonesia;

<sup>2</sup>Study Program of Medical, Faculty of Medical, Universitas Nahdlatul Ulama Surabaya, Jl. Jemursari No 51-57 Surabaya, East Java, Indonesia;

<sup>3</sup>Study Program of Public Health, Faculty of Health, Universitas Nahdlatul Ulama Surabaya, Jl. Jemursari No 51-57 Surabaya, East Java, Indonesia;

\*Corresponding author:

Ary Andini;  
Study Program of Medical Laboratory Technology, Faculty of Health, Universitas Nahdlatul Ulama Surabaya, Jl. Jemursari No 51-57 Surabaya, East Java, Indonesia;  
[aryandini@unusa.ac.id](mailto:aryandini@unusa.ac.id)

Received: 2023-03-04

Accepted: 2023-04-02

Published: 2023-04-26

### ABSTRACT

**Introduction:** The active substance of pyrethroids, especially dimefluthrin, in insect repellent not only plays a role in killing mosquitoes but is also toxic to human health. This study aims to analyze the effect of insect repellent exposure on the histopathological findings in the liver and kidneys of the Wistar rat.

**Methods:** This experimental study used 24 male wistar rats, which were divided into four groups, namely control, type of insect repellent, which included mat electric (dimefluthrin 0.566%), liquid electric (dimefluthrin 0.014%), and coil (dimefluthrin 0.031%), with a duration of exposure a day for 8 hours in 20 days.

**Results:** There was a significant effect of the type of insect repellent exposure on the histopathological findings of the liver and kidneys ( $p < 0.05$ ). This study also showed the highest rate of cell degeneration and necrosis in the liver and kidneys belonged to Mat electric repellent exposure in the liver and kidney. Higher concentrations of dimefluthrin in insect repellent have a significant effect on the histopathology of the liver and kidney.

**Conclusions:** The use of mosquito coils, electric mats, and liquid electricity for 8 hours over 20 days affects the histopathological evaluation of the liver and kidneys. The higher the concentration of dimefluthrin in insect repellent, the higher the level of damage.

**Keywords:** insect repellent, kidney, liver, pyrethroid, white rat.

**Cite This Article:** Andini, A., Veterina, L., Wikurendra, E.A., Syafruddin, A., Rimasari, D., Aida, M.N. 2023. Histopathological findings of the liver and kidneys of wistar rat exposed to insect repellent. *Bali Medical Journal* 12(2): 1330-1333. DOI: 10.15562/bmj.v12i2.4315

## INTRODUCTION

Mosquitoes are vectors of diseases such as malaria, filarial, and dengue fever that pose a risk to humans. The mosquito repellent is one solution to eradicate mosquito spread.<sup>1</sup> Mosquito repellent on the market mostly contains active substances from the pyrethroid group such as allethrin and dimefluthrin,<sup>2</sup> which are available in the form of fuel, spray, and electricity. Aerosols and the fumes of insect repellent can pollute the air and interfere with the respiratory system and human body organ functions. Smoke from mosquito repellent promotes free radicals that can affect the profile of leukocytes in the blood and cause lung damage.<sup>3</sup> Mosquito repellent smoke enters the body by inhalation through the nose and then enters the respiratory tract, which will carry the inhaled active substance into the lungs and into the bloodstream.<sup>4</sup>

Free radicals could be a trigger of

oxidative stress, which has an impact on damage to several organs, tissues, and cells in the liver and kidneys.<sup>5</sup> A previous study conducted by Armalina et al. (2020) reported that insect repellent exposure containing allethrin-type pyrethroid compounds for 12–24 hours over 18 days obtained microscopic results of the liver with hydropic degeneration and necrosis in the portal area, and microscopic examination of the kidneys obtained microscopic results of necrosis and hydropic degeneration.<sup>6</sup>

The pyrethroid compound, dimefluthrin, also has a good ability to control mosquitoes but is likely to have a high toxic effect on the body if used continuously for a long time.<sup>7</sup> This study focused on analyzing the effect of exposure to insect repellent on histopathological features of the liver and kidneys with various concentrations of the active substance of the pyrethroid group, particularly dimefluthrin.

## MATERIALS AND METHODS

### Study design and materials

This study is an in vivo experimental study. The study used 24 male Wistar rats weighing approximately 200 grams. These rats were divided into 4 groups, including 6 rats as a control group without exposure, 6 rats as a group exposed to electric mosquito coils containing dimefluthrin 0.566%, 6 rats as a group exposed to mosquito coils containing dimefluthrin 0.014%, and 6 rats were exposed to liquid electric mosquito repellent with dimefluthrin content of 0.031%. The duration of exposure was 8 hours per day for 20 days each, with ketamine (Ket-A-100) for anesthesia and a 10% formalin buffer fixative solution.

### Data collection procedures

Organ sampling using a set of surgical instruments, sample pots for storage of liver and kidney organs, and histopathology slides using several pieces of equipment consisting of a Thermo

Scientific microtome, slides, cover slips, label paper, and an Olympus CX-22 microscope to observe necrotic and degenerating cells. The solutions needed for tissue processing are alcohol, xylene, paraffin, and hematoxylin-eosin (HE) for staining.

The liver and kidneys of rats were taken on day 20 and then preserved in 10% formalin for fixation. The histopathological procedure of the liver and kidneys briefly included tissue processing, sectioning with a microtome, HE staining, and observation under a microscope with 1000x magnification.

### Data analysis

Histopathological observation data of the liver and kidney were analyzed using the Kruskal-Wallis test because the data were non-parametric. The result is considered significant if  $p < 0.05$ . Histopathological findings in the kidneys and liver were identified by observing the necrotic and degenerating cells based on the interpretation data scores in Table 1.

## RESULTS

The following is the damage that occurs due to exposure to insect repellent for 8 hours per day for 20 days, based on histopathological observations of liver and

kidney tissue. Statistical tests using the Kruskal-Wallis test can be seen in Table 2 and 3.

Based on the statistical difference test, the results are obtained  $p$ -value  $< 0.05$ , which means that there was an effect of the type of insect repellent exposure on the histopathological findings of the liver and kidneys. Furthermore, the histopathological results of the liver and kidneys showed that exposure to electric mosquito pad, coils and liquid electric for 8 hours per day in 20 days were not safe to use every day because of the effect on cell degeneration and necrosis. In the negative control group without exposure to insect repellent, the liver and kidneys showed normal cell results without any damage (Figure 1-4).

## DISCUSSION

The spread of mosquito repellent currently only manifests the ability to kill and repel

mosquitoes without the risk of harming humans due to the long-term use of active toxic substances.<sup>9</sup> The active substance in insect repellent is very dangerous if used over the long term. One of the active ingredients in insect repellent is dimethylthrin.

The active substance of dimethylthrin in insect repellent has the characteristic of being able to knock down mosquitoes very quickly.<sup>10</sup> Dimethylthrin, when inhaled and entering the body, becomes a highly reactive compound that can cause exogenous reactive oxygen species (ROS) from environmental pollutants. These particles will become free radicals, which will inhibit deoxyribonucleic acid (DNA) production and damage lipid membranes. When free radicals in the body increase, antioxidants will decrease and increase the amount of oxidative stress. Oxidative stress will cause cell and tissue damage in the liver and kidneys.<sup>11</sup>

**Table 1.** Scores of histopathological findings in tissue.<sup>8</sup>

Score	Damage	Percentage of Damage
0	None	0%
1	Necrosis or cell degeneration reach $\frac{1}{4}$ of total observed	25%
2	Necrosis or cell degeneration reach $\frac{1}{2}$ of total observed	50%
3	Necrosis or cell degeneration reach $\frac{3}{4}$ of total observed	75%
4	Complete necrosis or cell degeneration	100%

**Table 2.** The difference of kidney cells damage in each group by using the Kruskal-Wallis test.

Group	N	Cells Damage		Percentage of Liver Cell Damage	Cells Degeneration (p-value)	Cells Necrotic (p-value)
		Degeneration	Necrosis			
Control	6	0.0	0.0	None		
Mat Electric	6	3.0	1.5	Degeneration 75% and necrotic 37.5%		
Coils	6	0.2	1.0	Degeneration 5% and necrotic 25%	0.002	0.019
Liquid electric	6	2.0	1.0	Degeneration 50% and necrotic 25%		

N = number of rats; Significant p-value ( $p < 0.05$ )

**Table 3.** The difference of liver cells damage in each group by using the Kruskal-Wallis test.

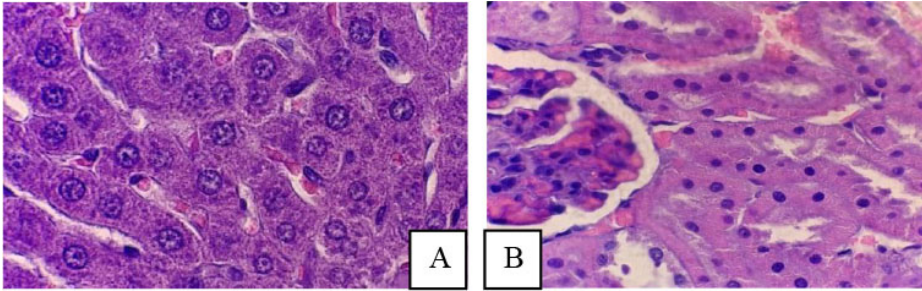
Group	N	Cells Damage		Percentage of Liver Cell Damage	Cells Degeneration (p-value)	Cells Necrotic (p-value)
		Degeneration	Necrosis			
Control	6	0.0	0.0	None		
Mat Electric	6	3.0	0.8	Degeneration 75% and necrotic 20%		
Coils	6	2.8	0.6	Degeneration 70% and necrotic 15%	0.000	0.030
Liquid electric	6	2.3	0.8	Degeneration 57.5% and necrotic 20%		

N = number of rats; Significant p-value ( $p < 0.05$ )

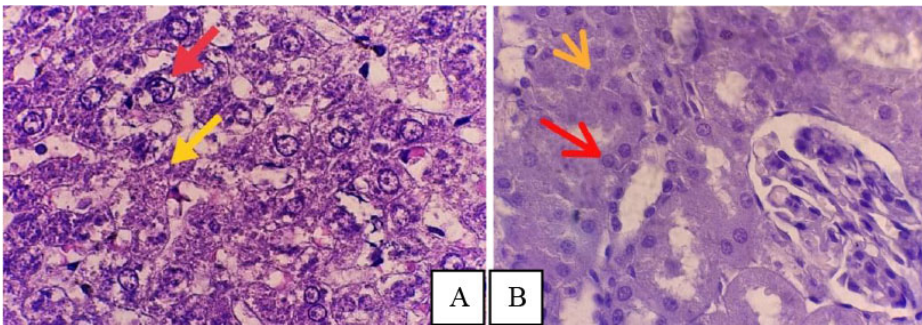


The liver is an excretory organ that can be used to detoxify toxic substances in the body. When the liver has enough toxic substances for a long period of

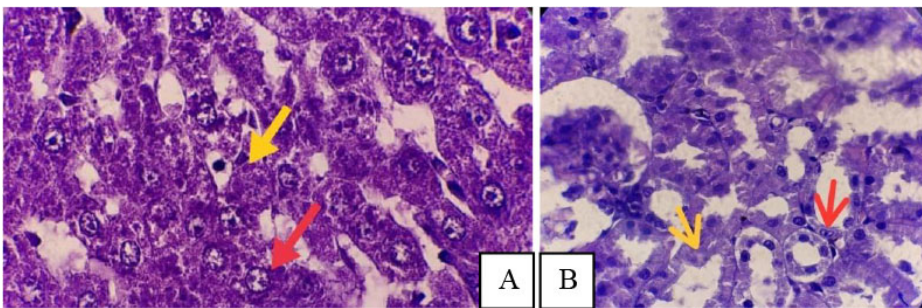
time, hepatocyte cells undergo changes such as fat degeneration and necrosis.<sup>12</sup> Meanwhile, kidneys are organs that are susceptible to the influence of chemicals,



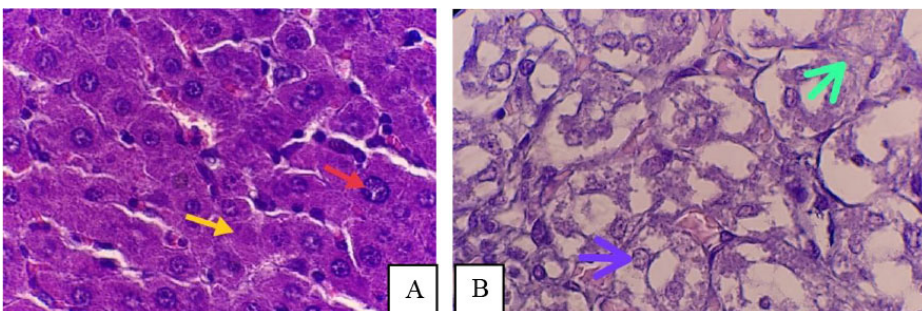
**Figure 1.** The histopathological findings in (A) normal liver, (B) normal kidney.



**Figure 2.** Histopathology of a degenerated and necrotic Wistar rat exposed to an electric repellent (A) liver, (B) kidney. The red arrows indicate cells degeneration and yellow arrows indicate necrosis (magnification 1000x).



**Figure 3.** Histopathology of cells degenerated and necrotic in Wistar rat exposed to mosquito coils repellent (A) liver, (B) kidney. The red arrows indicate cells degeneration and yellow arrows indicate necrosis (magnification 1000x).



**Figure 4.** Histopathology of cells degenerated and necrotic in Wistar rat exposed to liquid electric repellent (A) Liver, red arrows indicate degeneration and yellow arrows indicate hepatic necrosis. (B) Kidney, blue arrows indicate degeneration and green arrows indicate necrosis (magnification 1000x).

because the kidneys can receive 25-30% of blood circulation to be cleaned so that these organs can be filtered so that pathological changes are very high.<sup>13</sup>

Cell degeneration and necrosis in the liver and kidney organs could be signs of an unhealthy organ condition. This degeneration occurs due to an increase in free radicals, and if this degeneration damage cannot occur, then necrosis damage occurs. Necrosis is irreversible damage that can cause death or cannot return to its normal form.<sup>14</sup> This degenerative damage has the characteristics of cell swelling, the presence of empty spaces (vacuoles), and enlarged and compressed cells.<sup>15</sup> This necrotic cell damage has characteristics with the nucleus being wrinkled, no longer vascular, the nucleus does not look denser, tears occur (karioresis), and the nucleus becomes pale or not real.<sup>16</sup>

This research showed that the higher the concentration of the active substance in the mosquito repellent, the higher the damage to degeneration and necrosis that occurs in the liver and kidneys. Statistical analysis explained that there was exposure to insect repellent based on the histopathological findings in the liver and kidneys of rats. This study found necrosis and cell degeneration on exposure to insect repellent rods, liquid electricity, and electric rods in the liver and kidneys. In the kidneys and liver, the highest damage occurred with exposure to electric mosquito coils. The active substance, dimethrin, increased liver and kidney tissue damage, especially necrosis and degeneration of liver and kidney tissue. A previous study with a different active substance reported that the kidney and liver in rats were considerably microscopically damaged by allethrin inhalation doses administered 12 and 24 hours apart ( $p < 0.05$ ). During the kidney examination, necrosis, hydropic degeneration, lymphocyte, and erythrocyte infiltration were discovered. The liver showed necrosis in portal areas, hydropic degeneration of lobules, infiltration of inflammatory cells, and fibrosis in the portal area.<sup>6</sup> The limitation of this study is that it cannot explain the effect of dimethrin in insect repellents with different durations of exposure, so further research is needed to obtain more comprehensive research results.

## CONCLUSION

The use of mosquito coils, electric mats and liquid electricity for 8 hours in 20 days affects the histopathological evaluation of the liver and kidneys. The higher concentration of dimefluthrin in insect repellent, the higher the level of damage, and vice versa, if the lower the concentration of dimefluthrin in the insect repellent, the less damage will occur to the liver and kidneys. In future studies, the duration of exposure to mosquito coils containing dimefluthrin can be varied as extended to determine the specific effect of the dimefluthrin content.

## ACKNOWLEDGMENT

Thank to Lembaga Penelitian dan Pengabdian Masyarakat, Universitas Nahdlatul Ulama Surabaya to support the study through research grants No. 161.3/UNUSA/Adm-LPPM/III/2021.

## FUNDING

Research grants from Lembaga Penelitian dan Pengabdian Masyarakat, Universitas Nahdlatul Ulama Surabaya

## ETHICAL APPROVAL

This research has approved the ethical clearance through No.062/EC/KEPK/UNUSA/2021.

## CONFLICT OF INTEREST

The authors declare no conflict of interest.

## AUTHOR CONTRIBUTIONS

When conducting research and creating publications, each Author makes an equal contribution.

## REFERENCES

1. Al-Mamun MA, Aatur Rahman M, Habibur Rahman M, Hoque KMF, Ferdousi Z, Matin MN, et al. Biochemical and histological alterations induced by the smoke of allethrin based mosquito coil on mice model. *BMC Clin Pathol*. 2017;17:19. doi: [10.1186/s12907-017-0057-9](https://doi.org/10.1186/s12907-017-0057-9)
2. Srinita G, Fuadi LN, Nazarudin N. PERBANDINGAN EFEKTIVITAS OBAT NYAMUK LISTRIK MAT YANG MENGANDUNG D-ALLETHRIN-TRANSFLUTHRIN DENGAN DIMEFLUTHRIN TERHADAP NYAMUK *Aedes aegypti* SEBAGAI VEKTOR DEMAM BERDARAH DENGUE. :1-10.
3. Andini A, Hasanah M, Azizah SN, Rosyadahan AR, Rimasari D, Triapadma W, et al. The Effect of Insect Repellent Exposure on Leukocyte Profile and Histopathologic Findings in Lungs. *Biointerface Res Appl Chem*. 2022;12(6):7796-803. doi: <https://doi.org/10.33263/BRIAC126.77967803>
4. Prihati DR, Nugraheni I. PENGARUH PAPAN OBAT NYAMUK TERHADAP KADAR HEMOGLOBIN TIKUS BETINA USIA PUBERTAS Dwi Retna Prihati, Intan Nugraheni. *J Terpadu Ilmu Kesehatan*. 2015;4(2):90-3.
5. Niswah C, Syarifah, Sany F. PENGARUH ASAP ANTI NYAMUK KERTAS BAKAR TERHADAP JUMLAHERITROSIT PADA MENCIT (*Mus musculus L.*). *J SainHealth*. 2018;2(1):40-5.
6. Armalina D, Witjahjo B, Susilaningih N, Article O. Histopathological changes in liver, kidney and teratogenic effects of mice on exposure to mosquito repellent. *J Kedokt dan Kesehat Indones*. 2021;12(1):11-8. doi: [10.20885/JKKI.Vol12.Iss1.art4](https://doi.org/10.20885/JKKI.Vol12.Iss1.art4)
7. Muhidin H, Rasmartini T. Perbandingan Efektivitas Obat Nyamuk Bakardan Elektrik dengan Bahan Aktif Dimeflutrin terhadap Nyamuk *Culex sp* Mahasiswa Program Pendidikan Sarjana Kedokteran Universitas Islam Bandung, Dosen Fakultas Kedokteran Universitas Islam Bandung A. *Pendahuluan. Pros Pendidik Dr*. 2015;513-8.
8. Agata A, Widiastuti EL, Susanto GN. Respon Histopatologis Hepar Mencit (*Mus musculus*) yang Diinduksi Benzo ( $\alpha$ ) Piren terhadap Pemberian Taurin dan Ekstrak Daun Sirsak (*Annona muricata*). *J Natur Indones*. 2016;16(2):54-63.
9. Dahniar A. Pengaruh Asap Obat Nyamuk Terhadap Kesehatan dan Struktur Histologi Sistem Pernafasan. *J Kedokt Syiah Kuala*. 2011;11(1):52-9.
10. Juhryyah SRI. Gambaran histopatologi organ hati dan ginjal tikus pada intoksikasi akut insektisida (metofluthrin, d-phenothrin, d-allethrin) dengan dosis bertingkat. 2008.
11. Laksana ASD, Kusumasita L, Faniyah F. Ameliorative effect of 50 % ethanol extract of moringa leaves (*Moringa oleifera Lam.*) on lead-induced oxidative stress in the liver of male wistar rat model. *Bali Med J*. 2022;11(3):1887-91. doi: [10.15562/bmj.v11i3.3728](https://doi.org/10.15562/bmj.v11i3.3728)
12. Sijid SA, Muthiadin C, Zulkarnain, Hidayat AS, Amelia RR. Pengaruh Pemberian Tuak terhadap Gambaran Histopatologi Hati Mencit (*Mus musculus*) ICR Jantan. *J Pendidik Mat dan ipa*. 2020;11(2):193-205. doi: [dx.doi.org/10.26418/jpmipa.v11i2.36623](https://doi.org/10.26418/jpmipa.v11i2.36623)
13. Rinalty EDD, Soekanto A, Sahadewa S. Jus Buah Naga sebagai Antioksidan pada Tikus Putih (*Rattus norvegicus*) yang Dipapar Obat Anti Nyamuk Bakar terhadap Perubahan Histopatologi Sel Nephron. *J Ilm Pendidik Eksakta*. 2017;3(3):235-49.
14. Andreas H, Trianto HF, Ilmiawan MI. Gambaran Histologi Regenerasi Hati Pasca Penghentian Pajanan Monosodium Glutamat pada Tikus Wistar. *eJournal Kedokt Indones*. 2015;3(1):29-36. doi: [10.23886/ejki.3.4804](https://doi.org/10.23886/ejki.3.4804)
15. Suhita NLPR, Sudira IW, Winaya IBO. Histopatologi Ginjal Tikus Putih Akibat Pemberian Ekstrak Pegagan (*Centella asiatica*) Peroral. *Bul Vet Udayana*. 2013;5(2):71-8.
16. Adinata MO, Sudira IW, Berata IK. Efek Ekstrak Daun Ashitaba (*Angelica keiskei*) Terhadap Gambaran Histopatologi Ginjal Mencit (*Mus musculus*) Jantan. *Bul Vet Udayana*. 2012;4(2):55-62.



This work is licensed under a Creative Commons Attribution