

SURAT KETERANGAN

Nomor: 279/UNUSA/Adm-LPPM/III/2021

Lembaga Penelitian dan Pengabdian Kepada Masyarakat (LPPM) Universitas Nahdlatul Ulama Surabaya menerangkan telah selesai melakukan pemeriksaan duplikasi dengan membandingkan artikel-artikel lain menggunakan perangkat lunak **Turnitin** pada tanggal 22 Maret 2021.

Judul : *In vivo Effectivity of Collagen Extract from Clarias gariepinus (Burchell, 1822) 'Sangkuriang' on Formation of Malondialdehyde and Macrophages in Burn Healing*

Penulis : Ary Andini, Retno Handajani, Soetjipto Koesnowidagdo, Miranda Zawazi Ichsan, Luciano Pighinelli

No. Pemeriksaan : 2021.03.30.149

Dengan Hasil sebagai Berikut:

Tingkat Kesamaan diseluruh artikel (*Similarity Index*) yaitu 9%

Demikian surat keterangan ini dibuat untuk digunakan sebagaimana mestinya.

Surabaya, 30 Maret 2021

Ketua LPPM



**UNUSA
LPPM**

Achmad Syafiuddin, Ph.D
NPP: 20071300

LPPM Universitas Nahdlatul Ulama Surabaya

Website : lppm.unusa.ac.id

Email : lppm@unusa.ac.id

Hotline : 0838.5706.3867

PPAS

by Ary Andini

Submission date: 22-Mar-2021 12:49AM (UTC-0700)

Submission ID: 1539170454

File name: LS-576_FINAL.pdf (917.91K)

Word count: 2857

Character count: 15508



***In vivo* Effectivity of Collagen Extract from *Clarias gariepinus* (Burchell, 1822) ‘Sangkuriang’ on Formation of Malondialdehyde and Macrophages in Burn Healing**

Ary Andini^{1*}, Retno Handajani², Soetjipto Koesnowidagdo², Miranda Zawazi Ichsan³, and Luciano Pighinelli⁴

¹Faculty of Health, Nahdlatul Ulama University of Surabaya,
Jl. Jemursari No. 51-57, Surabaya 60237, Indonesia

²Department of Biochemistry, Faculty of Medicine, Airlangga University,
Jl. Mayjen Prof. Dr. Moestopo No. 47, Surabaya 60132, Indonesia

³College of Bioengineering, Chongqing University, No. 174 Shazheng Street, Shapingba District,
Chongqing 400044, People’s Republic of China

⁴Biomatter P&D and Innovation Biomaterials Lab. Incubadora Empresarial do Centro de
Biotecnologia – IECBiot Av. Bento Gonçalves, 9500, Prédio 43421 - Setor IV Campus do Vale
da UFRGS, Bairro Agronomia, CEP 91501-970, Porto Alegre – RS, Brazil

Abstract: Topical collagen on skin wound gift moist state that could stimulate reepithelization, proliferation, and epithelial cell migration to conduct growth factor activity on the wound area. One of the sources of collagen is Sangkuriang catfish [*Clarias gariepinus* (Burchell, 1822) ‘Sangkuriang’] skin that had low immunoreactivity in the human body. This study aimed to determine the influence of topical treatment with Sangkuriang catfish skin extract on malondialdehyde serum and macrophage total on burn injury. Collagen of Sangkuriang catfish skin was extracted by HCl 2 % for 48 h and neutralized by NaOH 1 M. Sangkuriang catfish skin extract contained amino acid of collagen that could repair and stimulate skin cell. This study was an experimental study that used 24 male *Rattus norvegicus* strain Wistar were divided into K3, P3, K10, and P10 groups. K group was treated with aquadest topical as a burn healing treatment for 3 d (K3) and 10 d (K10). The P group was treated with topical collagen extract as a burn healing treatment for 3 d (P3) and 10 d (P10). The results showed that treatment by collagen from Sangkuriang catfish skin could not decrease MDA serum on 3rd d and 10 d because of $P > 0.05$ ($P = 0.713$). Furthermore, it could not decrease macrophage total on 3rd d ($P = 0.427$) but significantly decrease to 10 d for K10 and P10. Collagen topical from Sangkuriang catfish could accelerate burn to heal by decreasing macrophages total on 10th d due to $P < 0.05$ ($P = 0.000$).

Keywords: Burn injury, Catfish, Collagen extract, Skin, Wound healing

1. INTRODUCTION

Wound burn is a trauma condition on tissue skin due to any contact with fire, heat steam, hazardous chemicals, electrical goods, and electromagnetic radiation [1]. The burn is one of quite serious in a healthy problem. In 2012 recorded 25 % or 23.8 % cases of full-thickness degree burn injury from 105 burn injury cases total that needed burn treatment at a burn unit in Dr. Soetomo Hospital, Surabaya,

Indonesia. Prevalence of full-thickness degree burn injury needed longer time for healing due to skin damage reached almost entire dermis with hypertrophic scar formation [2]. Therefore, burns require special treatment for accelerating burn healing, such as topical collagen.

Collagen has a main role in the wound healing process [3, 4] due to collagen contained high amino acid such as glycine that gift moist state on wound

Received: September 2019; Accepted: September 2020

*Corresponding Author: Ary Andini <aryandini@unusa.ac.id>

area to promote reepithelialization, stimulate proliferation and epithelial cell migration, induce growth factors activity and maintain nutrition transport [2, 4]. Besides, collagen is the main component of the extracellular matrix. Collagen extract from fish has advantages while compared with collagen from poultry and livestock because free from Bovine Spongiform Encephalopathy (BSE), Transmissible Spongiform Encephalopathy (TSE), and Foot and Mouth Disease (FMD), halal for used and had low immunoreactivity in the human body [4]. Sangkuriang catfish [*Clarias gariepinus* (Burchell, 1822) 'Sangkuriang'] is one type of catfish widely cultivated in Indonesia. This catfish is included in superior varieties that have been developed by researchers in Indonesia. The use of catfish skin as a source of collagen can reduce fish waste from the frozen fish food home industry that is developing in the city of Sidoarjo, East Java Province, Indonesia.

Wound healing consists of four phases that are homeostasis phase, inflammation phase, proliferation phase, and remodeling phase [5]. Stress oxidative affects any degenerative process and acute or chronic inflammation on wound area [6, 7]. Along with stress oxidative, macrophages exceed oxygen-dependent haem oxygenase and system transport as protection from ROS (Reactive Oxygen Species). Malondialdehyde (MDA) is a catabolism product of sulfolipid membrane that indicated oxidative stress presence [7]. This study aimed to determine the effect of topical collagen from Sangkuriang catfish [*Clarias gariepinus* (Burchell, 1822) 'Sangkuriang'] skin on malondialdehyde levels and macrophages total of skin burn healing.

2. MATERIALS AND METHODS

Sangkuriang catfish skin was obtained from waste of nugget home industry in Tanggulangin district, Sidoarjo city, East Java Province Indonesia. Extraction of catfish skin used HCl 2 % for 48 h and neutralized by NaOH 1 M until collagen fiber appears [4, 8]. Furthermore, 24 male *Rattus norvegicus* (Berkenhout, 1769) strain *Wistar* aged 3 mo and weighing about 200 g to 250 g with full-thickness degree burns on its back. There was the control group for 3 d (K3) and 10 d (K10), and a treatment group for 3 d (P3) and 10 d (P10). K3 and K10 groups were treated by using aquadest topical 0.05 mL on burns, whereas P3 and P10 groups

were treated by using topical collagen Sangkuriang catfish skin extract 0.05 mL on burns for each twice a day.

Malondialdehyde (MDA) serum levels of K3, K10, P3, and P10 groups were conducted by using 500 μ L serum for each *R. norvegicus* in a predefined group. Furthermore, 4.5 mL of cold PBS solution was added. The supernatant was taken 4 mL, then added 1 mL of 15 % TCA and given 1 mL of 0.37% TBA in 0.25 N HCl then heated in a water bath at temperature 80 °C for 15 min. Then cooled at room temperature for 60 min and centrifuged at 3 000 rpm for 15 min. Measurement of the absorbance of the MDA levels was analyzed using Boeco Germany at $\lambda = 532$ nm based on the standard curve (standard) of MDA solution.

The number of macrophages carried by histopathological tests that were taken from burn specimens, at the back edge of the burn to the depth of the muscles. Specimens were taken and put into fixative solution 10 % formalin. Furthermore, the specimen was conducted histopathological processing with Hematoxylin Eosin (HE) staining. The macrophages are identified by an irregular shape with a nucleus of more than 1 large. Histopathological observations were carried out with a binocular microscope CX-21 graticule lens, 400x magnification, and taking images with a CX-31 trinocular microscope.

The research has been approved by Animal Care and Use Committee of the Faculty of Veterinary Medicine, Airlangga University, Indonesia, through a certificate of ethical eligibility No. 447-KE.

3. RESULTS AND DISCUSSIONS

3.1 Malondialdehyde (MDA)

Malondialdehyde levels were analyzed with Analysis of Variance (ANOVA). The results showed that malondialdehyde serum levels on the P3 group were lower than K3, also MDA serum levels on the P10 group were lower than K10 but statistically had no significant differences in each group because of $P > 0.05$ ($P = 0.713$). Therefore data could not be analyzed with Post Hoc LSD test Malondialdehyde serum levels on *R. norvegicus* burns were shown in Table 1.

Table 1. MDA serum levels of *R. norvegicus* burns

| Treatment group | N | Mean \pm SD (nmol mL ⁻¹) | F | P |
|-----------------|---|--|-------|-------|
| K3 | 6 | 5.247 \pm 3.633 ^a | | |
| P3 | 6 | 4.005 \pm 1.633 ^a | 0.460 | 0.713 |
| K10 | 6 | 5.189 \pm 0.945 ^a | | |
| P10 | 6 | 4.693 \pm 0.709 ^a | | |

*superscript showed difference number statistically significant (p-value < 0.05)

3.2 Macrophages

Conformational macrophages total were stained by hematoxylin-eosin of histopathology test. Afterward, observed by microscope with 400x magnification. Macrophages were shown by irregular cells with nucleus more than one. Macrophages of each group showed in Figure 1. Macrophages total data were analyzed statistically with ANOVA (Analysis of Variance) then analyzed with Post Hoc LSD test because of $P = 0.000$. Data were shown in Table 2 and Table 3.

Based on Table 2 and Table 3 showed that macrophages total on P3 was lower than K3, but had no significant differences statistically due to $P > 0.05$ ($P = 0.427$). Meanwhile, macrophages total on P10 was lower than K10 and had significant differences statistically due to $P < 0.05$ ($P = 0.000$).

3.3 Sangkuriang Catfish Collagen Extract on Burn Healing Process

Wound healing is a complex biological process and dynamic process to repair injured cellular structures and tissue layers [9, 10]. There are four steps of wound healing process namely, (i) homeostasis phase that activates platelets to initiate coagulation cascade, (ii) inflammation phase that neutrophils, macrophages, and lymphocytes activation occur, (iii) proliferation phase that extracellular matrix formation begins, and (iv) remodeling that maturation of new matrix happens [2, 5, 11].

The optimal wound healing process requires adequate nutrition and protein that stimulates capillary formation, fibroblast proliferation, proteoglycan synthesis, collagen synthesis, and extracellular matrix remodeling [2, 9]. One of adequate protein intake from fish, such as collagen from skin or scales, bones, and meat fish that can be essential for optimizing wound healing because of its quality [12–14].

Sangkuriang catfish extract contained amino acid such as glycerin and hydroxyproline that compose of collagen as used for topical treatment on the wound area. Impairment of burn healing due to the enhancement of free-radicals-mediated damage reduced angiogenesis and decreased collagen reorganization that could be leading to a chronic wound. Unhealed wounds constantly stimulate inflammatory mediators that caused pain and swelling at the wound site [2, 5].

Enhancement of Reactive Oxygen Species (ROS) has indicated inflammation phase happened. It could induce MDA levels in the wound area, therefore, stimulate MDA levels in serum [7]. Topical collagen Sangkuriang catfish could reduce MDA levels in serum on 3rd d and 10th d descriptively, but statistically not significant those were shown in Table 1 and Fig. 1. Topical Sangkuriang catfish extract reducing ROS activity on wound skin but had not related directly with blood plasm. Therefore, topical collagen treatment on burns had not been affected significantly in animal models serum.

Burns could stimulate lipid peroxidase to produce MDA after 48 h post-injury that was starting on 3rd d, 5th d, 7th d, and 10th d that appropriate to kind of burns and body injury location [7]. Macrophages could eliminate bacteria by producing Reactive Oxygen Species (ROS) [2]. However, free radicals with high quantity could generate impaired wound healing that caused damage to cellular membranes, nucleotides, protein, and lipids [7]. Furthermore, enhancement of macrophages total was going to increase MDA levels. Otherwise, the reduction of macrophages total was going to decrease the MDA level [2, 15].

Collagen extract from Sangkuriang catfish could decrease macrophages total on the wound area. Based on histopathology result test showed that descriptively total macrophages on 3rd d of

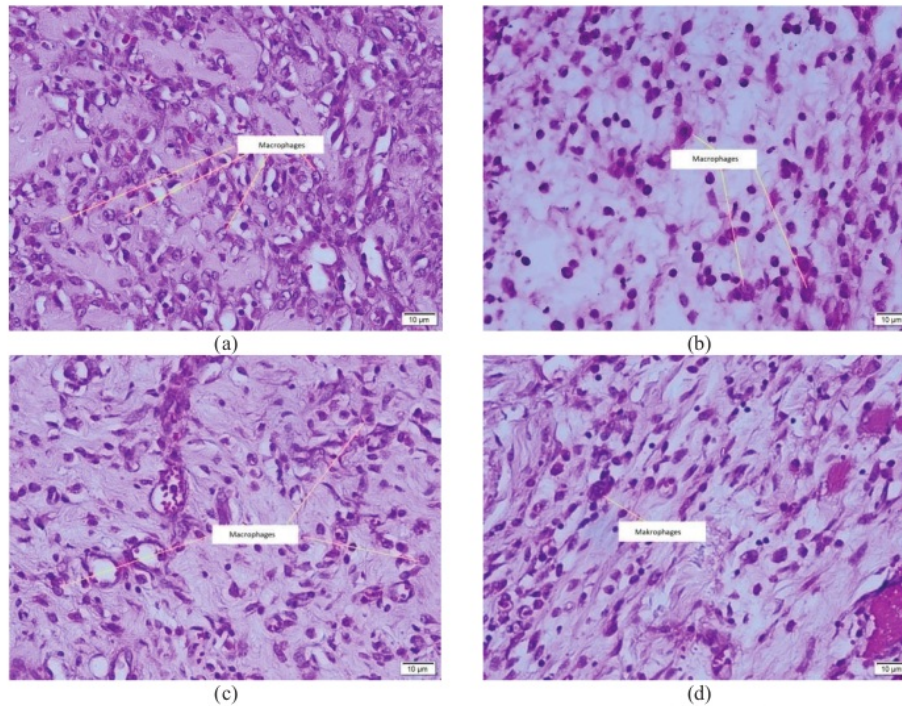


Fig. 1. Macrophages of *R. norvegicus* skin burn, (a) macrophages on K3 group, (b) macrophages on P3 group, (c) macrophages on K10 group and macrophages on P10 group.

Table 2. Macrophages total of *R. norvegicus* burns

| Treatment group | N | Mean \pm SD | F | p |
|-----------------|---|---------------------------------|--------|-------|
| K3 | 6 | 13.778 \pm 2.509 ^a | 36.842 | 0.000 |
| P3 | 6 | 11.612 \pm 1.306 ^a | | |
| K10 | 6 | 29.611 \pm 3.623 ^b | | |
| P10 | 6 | 21.111 \pm 4.520 ^c | | |

*superscript showed difference number statistically significant (p-value < 0.05)

Table 3. p-value of post hoc test on macrophages total of *R. norvegicus* burns

| Treatment group | K3 | P3 | K10 | P10 |
|-----------------|----|-------|-------|-------|
| K3 | | 0.427 | 0.000 | 0.001 |
| P3 | | | 0.000 | 0.000 |
| K10 | | | | 0.000 |
| P10 | | | | |

* Post Hoc LSD test (p-value < 0.05)

P3 group was lower than K3 group, also on 10th d showed that descriptively macrophages total of P10 group was lower than K10 group and had significant statistically that were shown in Table 2 and Table 3. Topical collagen extract could decrease macrophages total that wound healing was going to quickly ends until the proliferation phase came and stimulate matrix extracellular (ECM) formation.

Macrophages total reached on 3rd d until 5th d post-injury. As healing time progresses, macrophages total was going to decrease when proliferation phase occurs, then remodeling phase came. Therefore macrophages total on 3rd d on K3 and P3 groups had no significant differences.

Differentiation of monocytes that had migrated from the vascular to the side of the wound area could

stimulate macrophages releasing. Macrophages could promote cell repair by influencing their recruitment, positioning, differentiation, and function within a damaged tissue [10]. Inflammatory monocytes and macrophages were key regulators of tissue repair, regeneration, and fibrosis [10]. Topical collagen as a biomedical application in wound healing has hypoallergenic and safe properties that very attractive for experimental and future clinical applications [16].

4. CONCLUSIONS

Collagen topical from Sangkuriang catfish [*Clarias gariepinus* (Burchell, 1822) 'Sangkuriang'] could not decrease malondialdehyde levels significantly on 3rd d and 10th d, also macrophage total on 3rd d. But could decrease macrophage total significantly on 10th d. Therefore, Collagen topical from Sangkuriang catfish could accelerate burn healing by decreasing macrophages total on 10th d. Collagen extract from Sangkuriang catfish is expected to be developed in further research as an effective treatment for the burns healing process.

5. ACKNOWLEDGEMENTS

Partially of research publication was supported by the Institute of Research and the Community Empowerment Nahdlatul Ulama University of Surabaya. Also thanks to lectures of the Biochemistry and Molecular Biology Department, Airlangga University had already supported this research.

5. REFERENCES

1. A. Soni, V.K. Dwivedi, M. Chaudhary, S.M. Shrivastava and V. Naithani. Efficacy of ampucare: A novel herbal formulation for burn wound healing versus other burn medicines. *Asian Journal of Biological Sciences* 3(1): 18–27 (2010).
2. T.S.N. Hidayat. *Peran Topikal Ekstrak Gel Aloe Vera pada Penyembuhan Luka Bakar Derajat Dalam pada Tikus [Role of Topical Extract Aloe Vera Gel in Deep Burn Wound Healing in Rat]*. [Thesis]. School of Medicine, Airlangga University, Surabaya, Indonesia (2013). (in Bahasa Indonesia).
3. A. Gaspar, L. Moldovan, D. Constantin, A.M. Stanciuc, B.P.M. Sarbu and I.C. Efrimescu. Collagen-based scaffold for skin tissue engineering. *Journal of Medicine and Life* 4(2): 172–177 (2011).
4. A. Andini, R. Handajani and Soetjipto. Sangkuriang catfish (*Clarias gariepinus* var) skin extract activity on fibroblast and collagen synthesis for skin burn healing. *Proceeding Surabaya International Health Conference* 1(1): 347–351 (2017).
5. B.P. Nagori, and R. Solanki. Role Medicinal plants in wound healing. *Research Journal of Medicine Plant* 5(4): 392–405 (2011).
6. R. Geethalakshmi, C. Sakravarthi, T. Kritika, M.A. Kirubakaran and D.V.L Sarada. Evaluation of antioxidant and wound healing potentials of *Sphaeranthus amaranthoides* Burm.f. *BioMed Research International* 2013: 1–7 (2013).
7. C. Spulber. *Oxidative Stress-Implications in Burn Patient Undergo Surgery*. [PhD Thesis]. University of Medicine and Pharmacy Craiova, Romania (2011).
8. D.A.P Puspitasari, V.P. Bintoro and B.E. Setiani. The soaking effect on different hydrochloride acid level and soaking time on pH, swelling percentage and collagen yield of chicken shank bone. *Journal of the Indonesian Tropical Animal Agriculture* 38(2): 98–102 (2013).
9. H. Sorg, D.J. Tilkorn, S. Hager, J. Hauser, and U. Mirastschijski. Skin wound healing: An update on the current knowledge and concepts. *European Surgical Research* 2017;58:81–94.
10. T.A. Wynn, and K.M. Vanella. Macrophages in tissue repair, regeneration, and fibrosis. *Immunity* 44(3): 450–462 (2016). DOI: 10.1016/j.immuni.2016.02.015.
11. L.M. Leong, A.Z. Sahalan, L.H. Tan, N.H. Mustafa and N.F. Rajab. *Clarias batrachus* collagen extract increases fibroblast cell adhesion, migration and proliferation. *Journal of Applied Pharmaceutical Science* 5(3): 19–23 (2015).
12. P. Rahayu, F. Marcelline, E. Sulistyaningrum, M.T. Suhartono and R.R. Tjandrawinata. Potential effect of striatin (DLBS0333), a bioactive protein fraction isolated from *Channa striata* for wound treatment. *Asian Pacific Journal of Tropical Biomedicine* 6(12): 1001–1007 (2016).
13. J. Zhang, W. Liu, and G. Li. Isolation and characterization of collagen from the skin of Largerfin Longbarbel Catfish (*Mystus macropterus*). *Food Chemistry* 115: 826–831 (2009).
14. K. Yamamoto, K. Igawa, K. Sugimoto, Y. Yoshizawa, K. Yanagiguchi, T. Ikeda, S. Yamada and Y. Hayashi. Biological safety of fish (Tilapia) collagen. *BioMed Research International* 2014: 1–9 (2014).
15. A. Ayala, M.F. Muñoz, and S. Argüelles. Lipid

peroxidation: Production, metabolism, and signaling mechanisms of malondialdehyde and 4-Hydroxy-2-Nonenal. *Hindawi Publishing Corporation Oxidative Medicine and Cellular Longevity* Article ID 360438: 1–31.

16. H. Sinno, M. Malhotra, J. Lutfy, B. Jardin, S. Winocour, F. Brimo, L. Beckman, K. Watters, A. Philip, B. Williams, and S. Prakash. The effects of topical collagen treatment on wound breaking strength and scar cosmesis in rats. *Canadian Society of Plastic Surgeons* 20(3): 181–185 (2012).

PPAS

ORIGINALITY REPORT

9%

SIMILARITY INDEX

7%

INTERNET SOURCES

7%

PUBLICATIONS

3%

STUDENT PAPERS

MATCH ALL SOURCES (ONLY SELECTED SOURCE PRINTED)

2%

★ dyuthi.cusat.ac.in

Internet Source

Exclude quotes Off

Exclude matches Off

Exclude bibliography Off