

## **SURAT KETERANGAN**

Nomor: 1212/UNUSA-LPPM/Adm-I/VII/2023

Lembaga Penelitian dan Pengabdian Kepada Masyarakat (LPPM) Universitas Nahdlatul Ulama Surabaya menerangkan telah selesai melakukan pemeriksaan duplikasi dengan membandingkan artikel-artikel lain menggunakan perangkat lunak **Turnitin** pada tanggal 04 Juli 2023

Judul : Correlation of magnetic angiography with relative cerebral blood flow on arterial spin labeling using magnetic resonance imaging in acute ischemic stroke patients

Penulis : Utami Ambarsari, Arif Faisal, Hari Basuki Notobroto, Erna Furaidah, Yunita Lestari Indrianto, Naura Anindya Candini

No. Pemeriksaan : 2023.07.06.421

Dengan Hasil sebagai Berikut:

**Tingkat Kesamaan diseluruh artikel (*Similarity Index*) yaitu 13%**

Demikian surat keterangan ini dibuat untuk digunakan sebagaimana mestinya.

Surabaya, 06 Juli 2023

Ketua LPPM



UNUSA  
LPPM

Achmad Syafiuddin, Ph.D

NPP: 20071300

**LPPM Universitas Nahdlatul Ulama Surabaya**

Website : lppm.unusa.ac.id

Email : lppm@unusa.ac.id

Hotline : 0838.5706.3867

# Correlation of magnetic

*by* AmbarsariUtami

---

**Submission date:** 04-Jul-2023 10:47AM (UTC+0700)

**Submission ID:** 2126271755

**File name:** document\_4.pdf (392.56K)

**Word count:** 4774

**Character count:** 25151

## Correlation of magnetic angiography with relative cerebral blood flow on arterial spin labeling using magnetic resonance imaging in acute ischemic stroke patients



Utami Ambarsari<sup>1\*</sup>, Arif Faisal<sup>1</sup>, Hari Basuki Notobroto<sup>2</sup>, Erna Furaidah<sup>3</sup>,  
Yunita Lestari Indrianto<sup>4</sup>, Naura Anindya Candini<sup>4</sup>

### ABSTRACT

**Introduction:** Acute ischemic stroke is one of the three main causes of death in developed countries. RISKESDAS data of 2013 depicted the fact that the prevalence rate of stroke was 12.1 per 1,000 population. CT protocol and magnetic resonance imaging (MRI) are excellent evaluations of acute ischemic stroke. Magnetic resonance angiography (MRA) is an MRI technique to delineate arteries and evaluate stenosis and occlusion. Arterial Spin Labeling (ASL) MRI is quantitative and non-invasive, does not require Gadolinium contrast, measures cerebral blood flow, is useful for performing perfusion-based functional MRI (fMRI), and is able to be reevaluated. The study aimed to analyze the correlation between MRA and the relative Cerebral Blood Flow on ASL in patients with acute ischemic stroke.

**Methods:** The study aimed to analyze the correlation between MRA and the relative Cerebral Blood Flow on ASL in patients with acute ischemic stroke.

**Results:** The patients with acute ischemic stroke were in the age category of 40 years or more (92.3%) with the average age of the patients was 56.96 years  $\pm$  14.05. The youngest patient was 8 years old and the oldest one was 79 years old. Most of them were women (56.5%) with the most comorbid hypertension (45.7%) and diabetes mellitus (34.8%). The results of the evaluation after agreeing the consent portrayed that MRA was normal in 10 patients (21.7%) and there was stenosis or occlusion in 36 patients (78.3%). ASL examination showed that 20 patients (43.5%) were normal, whereas 26 patients (56.5%) were decreased.

**Conclusion:** Phi value was 0.601 ( $p < 0.05$ ), meaning that there was a strong relationship between the results of MRA examination and ASL.

**Keywords:** acute ischemic stroke, mri-mra, asl.

**Objective This Article:** Ambarsari, U., Faisal, A., Notobroto, H.B., Furaidah, E., Indrianto, Y.L., Candini, N.A. 2022. Correlation of magnetic angiography with relative cerebral blood flow on arterial spin labeling using magnetic resonance imaging in acute ischemic stroke patients. *Bali Medical Journal* 11(3): 1310-1315. DOI: 10.15562/bmj.v11i3.3547

<sup>1</sup>Department of Radiology, Faculty of Medicine, Universitas Gajah Mada, Indonesia;

<sup>2</sup>Faculty of Public Health, Universitas Airlangga, Indonesia;

<sup>3</sup>Medical Staff of Radiology, Jemursari Islamic Surabaya Hospital, Indonesia;

<sup>4</sup>Faculty of Medicine, Universitas Brajijaya, Indonesia;

\*Corresponding author:

Utami Ambarsari;  
Department of Radiology, Faculty of Medicine, Universitas Gajah Mada, Indonesia;  
utamia89@gmail.com

Received: 2022-07-16

Accepted: 2022-08-02

Published: 2022-09-28

### INTRODUCTION

Acute ischemic stroke is one of the three leading causes of death in developed countries, i.e., one death for every 15-18 total deaths. The major causes of acute ischemic strokes encompass thromboembolism due to atherosclerosis of large arteries, cardiac embolism, and small vessel occlusion. Other causes include intracerebral hemorrhage (~12%) and subarachnoid hemorrhage (9%). The death rate associated with stroke has decreased over the past few years due to better general clinical care and stroke-specific treatment.<sup>1</sup>

With an incidence of about 17 million people worldwide suffering from a stroke

every year, acute ischemic stroke is the second leading cause of global death, following coronary artery disease. In connection with the data of Health Acute Ischemic Stroke in the United States of America, acute ischemic stroke has been the fifth leading cause of death with an incidence of 795,000 people per year.<sup>2</sup> Kisela et al., (2012) found that the incidence of stroke increases dramatically with age, especially those whose age was 55 years and more. In coping with similar cases in Asia, the incidence of stroke ranges from 116 to 483 per 100,000 population per year. Specifically, in Indonesia, based on RISKESDAS data of 2013, the prevalence of stroke was 12.1 per 1,000 population, covering ischemic (87%), hemorrhagic

(10%), and subarachnoid hemorrhage (3%).<sup>3</sup>

Neuroimaging is indeed vital for stroke assessment. CT and magnetic resonance imaging (MRI) protocols are excellent for the evaluation of acute ischemic stroke. In the CT protocol, the main goals of acute ischemic stroke imaging are to exclude bleeding and stroke-like lesions and to approach the management of choice for IV or IA for infarct expansion (core) and arterial occlusion. Magnetic resonance angiography (MRA) is a group of techniques based on magnetic resonance imaging (MRI) to image blood vessels. MRA is used to produce images of arteries and veins to evaluate stenosis (abnormal narrowing) and occlusion.<sup>4</sup>

Flow-related phenomena are recognized earlier in the development of MR before the imaging techniques are designed. Understanding the mechanisms of flow sensitivity and the appearance of flowing fluids is important for several reasons, including but not limited to low sensitivity used to provide diagnostic information. Diffusion Weighted Imaging and Apparent Diffusion Coefficient (ADC) are the most sensitive MRI modalities for imaging brain ischemia, with sensitivity up to 73-92% in the first 3 hours and up to 95-100% in the first 6 hours and necrosis. Perfusion imaging in adults with acute stroke often exhibits hypoperfusion in the ischemic core and around areas of non-diffusion-restricted penumbral tissue.<sup>5</sup>

Arterial Spin Labeling (ASL) is a non-invasive procedure in MRI technique to measure cerebral blood flow and has the ability to determine cerebral artery territory. It does not require Gadolinium contrast and is able to eliminate the risk of developing nephrogenic systemic fibrosis in patients with renal dysfunction. Moreover, it is advantageous for the pediatric people since it avoids the technical difficulties and problems of using contrast agents and reduces radiation exposure when performed with CT and nuclear medicine techniques. In addition, the technique of ASL is easy to repeat and useful for performing perfusion-based functional MRI (fMRI), where it can be reevaluated since it can change over time.<sup>6</sup> However, there are still several ASL's incapacitations such as low noise signal and artifacts compared to Dynamic Contrast Enhancement (DSC).<sup>7</sup>

The use of ASL has increased due to improvements and faster acquisition times and ease of post-processing. This has been reported in a retrospective cohort study conducted by Belani et al. (2020), of which the study aimed to report potential additional findings obtained for adding ASL to routine brain MRI examinations in patients with neurological indications.<sup>8</sup> In patients presenting to the emergency department beyond the golden period of plasminogen-intravenous-type, MRI has been recommended as a tool to identify individuals with salvageable brain tissue by detecting whether tissue hypoperfusion has progressed to irreversible ischemic

injury.<sup>9</sup> Many studies have been carried out in connection with TOF-MRA development. Although it has limitations, among others, it tends to overestimate, as well as length as stenosis, because it is influenced by turbulence and slow blood flow. Consequently, the distal side of the blood vessels is less accurate. However, the sensitivity of TOF-MRA has been accepted in the imaging of intracranial steno-occlusive lesions compared to digital subtraction angiography (DSA) and computed tomography angiography (CTA). Whereas contrast-enhanced MRA is used less frequently but provides additional information in terms of blood flow velocity and direction of flow.<sup>10</sup>

Problem formulation is a limitation in visualization on MRA that tends to be overestimated, as well as length as stenosis, because it is influenced by turbulence and slow blood flow. Consequently, the distal side of the blood vessels is less accurate. Moreover, the limitations of ASL in describing perfusion in ischemic areas are caused by several factors such as motion artifacts and low signal to noise. Therefore, the present study aimed to investigate the relationship between the results of MRA examination and the results of the relative examination of cerebral blood flow on ASL in acute ischemic stroke patients.

## METHODS

### Patients

The population of the study were all patients with acute ischemic stroke who were hospitalized or outpatient at PHC Surabaya Hospital in January 2019 to April 2021. A total of 46 patients with the diagnosis of acute ischemic stroke had a head MRI examination at PHC Surabaya Hospital in January 2019 to April 2021. The patient has met the inclusion and exclusion criteria. The inclusion criteria involved inpatients and outpatients at PHC Surabaya Hospital from January 2019 to April 2021, patients with acute ischemic stroke, and patients who had a head MRI examination (DWI, ADC, FLAIR, ASL, and MRA). The exclusion criteria included patients with a diagnosis of subacute and chronic ischemic stroke, incomplete medical record data, and patients with poor image quality due to

patient artifacts/movements.

### Data and Data Sources, Data Collection Techniques, and Instruments

The secondary data were obtained from electronic medical records of acute ischemic stroke patients treated at PHC Hospital. The main data used in this study were collected through documentation. In this study, electronic medical records were used to obtain data on acute ischemic stroke patients who were treated at PHC Surabaya Hospital during January 2019 to April 2021 and at the MRI work station in Radiology division of PHC Surabaya Hospital.

### Imaging Protocol

In this study, the instrument was a workstation, 1.5 T MRI (Discovery MR 750; GE Healthcare, Milwaukee, WI) at PHC Surabaya Hospital undertaken during January 2019 to April 2021. Standard stroke MRI protocols performed at the hospital included Diffusion Weighted Image (DWI), T2\*-weighted image (T2\*-WI), T2 FLAIR, T1WI, T2\*GRE, time of flight magnetic resonance angiography (TOF – MRA), and 3D ASL non-contrast on 1.5 Tesla MRI of all cases obtained from electronic medical records. The imaging sequence and parameters covered:

- DWI (FOV: 22 cm, matrix: 128 x 160 TR: 5449.0 ms, TE: 65 ms, slice thickness: 5 mm, spacing: 1.0 mm, number of slices: 22, b-factor: 1000, NEX = 2, and acceleration factor: 2)
- FLAIR (FOV: 22 cm, matrix: 288 x 192, TR: 6200 ms, TE: 120 ms, turning angle: 28°, slice thickness: 5 mm, spacing: 1.0 mm, and number of slices: 22)
- 3D ASL non contrast (FOV: 24.0, slice thickness: 4.0 mm, #of scan locs: 36, TR: 4843.0, max # slices: 106, TE(s) scan: 1.0, TE: 10.5)
- 3D TOF MRA (FOV: 22.0, phase FOV: 0.81, slice thickness 1.2 mm, slabs: 5, locs per slab: 38, minimum TR, TE(s) scan: 1.0, flip angle: 20, max slices: 256)

Evaluation of acute ischemic stroke lesions was identified through the assessment of the results of MRI-MRA imaging in stroke patients by a radiologist covering DWI and FLAIR imaging, 3D ASL, and 3D TOF MRA. Existing DWI results were confirmed with ADC.

**Image Interpretation**

Identifying the condition of the blood vessels was undertaken using the 3D TOF MRA sequence. If there was a blockage in the blood vessel, it showed a picture of stenosis in the blood vessel and occurred in only one location or in several locations.

ASL was identified based on imaging results where, in 3D ASL, it could be revealed as normal perfusion and a decrease in perfusion (hyperfusion). The results of ASL examination were interpreted by two assessors who were Radiology Specialists. The assessors had experienced in reading MRI results for at least 5 years. If the assessors' results showed a large difference and a low reliability, then an agreement test (Kappa coefficient) was carried out. The statistical analysis was conducted using Mc Nemar test and Kappa Coefficient test.

**Interpretation of MRA Examination Results**

Obtaining normal results or stenosis.

**Interpretation of ASL Examination Results**

The cerebral blood flow value referred to a value resulting from qualitative perfusion of blood flow in brain tissue. ASL Acquisition was a non-invasive one-click application that allowed measurement of whole-brain CBF. This contrast-free acquisition technique was ideal for patients who were contraindicated. The CBF map was automatically displayed when 3D ASL series were selected and Ready View was launched.

**RESULTS**

The patients with acute ischemic stroke were in the age category of 40 years or more (92.3%), with the average age of the patients was 56.96 years ± 14.05. The youngest patient was 8 years old and the oldest one was 79 years old. Most of them were women (56.5%) with the most comorbid hypertension (45.7%) and diabetes mellitus (34.8%). The results of the evaluation after agreeing the consent portrayed that MRA was normal in 10 patients (21.7%) and there was stenosis or occlusion in 36 patients (78.3%). ASL examination showed that 20 patients (43.5%) were normal, whereas 26 patients

(56.5%) were decreased.

**MRA Examination Results**

Table 1 shows the evaluation results of MRA examination carried out by two assessors.

**ASL Examination Results**

Table 2 depicts the evaluation results of ASL examination carried out by 2 assessors.

**Relationship between MRA and ASL**

The results of the evaluation conducted by two assessors on MRA and ASL examinations showed low or moderate reliability, therefore, an agreement was made between the two assessors due to the different examination results. After the agreement was taken, the results of MRA examination were normal in 10 patients (21.7%) and stenosis or occlusion in 36 patients (78.3%). In regard to ASL examination results, 20 patients (43.5%) were normal and 26 patients (56.5%) experienced decreased. Table 3 explains the relationship between the results of MRA and ASL.

The results showed that  $p = 0.601$  ( $p < 0.05$ ), which indicated a strong relationship between MRA and ASL examinations.

**DISCUSSION**

a. By age

In accordance with the results above, most patients at PHC Surabaya Hospital were in the age category of 40 years or more (92.3%) with the average age of the patients was 56.96 years ± 14.05. The youngest patient

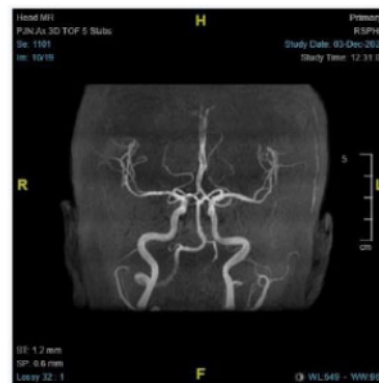

Figure 1. Overview of Normal MRA.

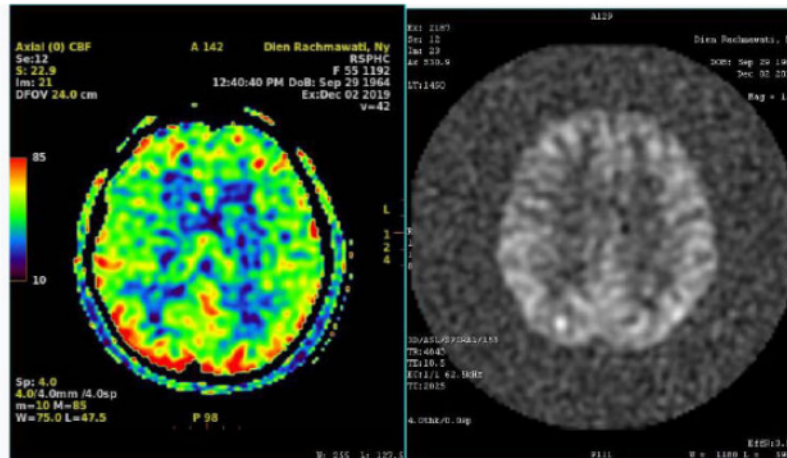


Figure 2. Overview of changes in color gradation in ASL showing a relatively normal cerebral blood flow.

Table 1. MRA examination results.

Assessor 1	Assessor 2		Total
	Normal	Stenosis	
Normal	7 (15.2%)	3 (6.5%)	10 (21.7%)
Stenosis	12 (26.1%)	24 (52.2%)	36 (78.3%)
Total	19 (41.3%)	27 (58.7%)	46 (100.0%)

Mc Nemar test  $p = 0.035$   
Kappa = 0.277  $p = 0.037$

**Table 2. ASL examination results.**

Assessor 1	Assessor 2		Total
	Normal	Decreased	
Normal	15 (32.6%)	6 (13.0%)	21 (45.7%)
Decreased	6 (13.0%)	19 (41.3%)	25 (54.3%)
Total	21 (45.7%)	25 (54.3%)	46 (100.0%)

Mc Nemar test  $p = 1.000$

Kappa=0.474  $p = 0.001$

**Table 3. Relationship between MRA and ASL.**

MRA	ASL		Total
	Normal	Decreased	
Normal	10 (21.7%)	0 (0.0%)	10 (21.7%)
Stenosis	10 (21.7%)	26 (56.5%)	36 (78.3%)
Total	20 (43.5%)	26 (56.5%)	46 (100.0%)

$p = 0.601$ ;  $p = 0.000$

**Table 4. Characteristics of acute infarct stroke cases at PHC Surabaya Hospital.**

Characteristics	Category	Frequency (%)	$\bar{x} \pm SD$ (Min.-Max.)
Age	< 20 y.o	1 (2.2%)	$56,96 \pm 14,05$ (8 – 79) y.o
	20 - <40 y.o	3 (6.5%)	
	40 - <60 y.o	20 (43.5%)	
	> 60 y.o	22 (47.8%)	
Gender	Male	20 (43.5%)	
	Female	26 (56.5%)	
Comorbid	Diabetes mellitus	16 (34.8%)	
	Hypertension	21 (45.7%)	
	Coronary disease	3 (6.5%)	
	Dyslipidaemia	2 (4.3%)	
	CVA	4 (8.7%)	
	SAH/SDH/ICH	3 (6.5%)	
	Malignancy	3 (6.5%)	
Others	4 (8.7%)		

was 8 years old and the oldest one was 79 years old. Similarly, Fauziah et al. (2012) examined the characteristics of Ischemic Stroke sufferers at Haji Adam Malik Hospital, Medan, and the incidence of stroke infarcts was highest in the age category of 55-64 years old with the prevalence of stroke in Indonesia reaching 8.3/1,000 population, aged over 40 years. The results of the present study were in accordance with the theory that stated that stroke occurred in productive ages and increased in the elderly.<sup>11</sup>

b. By gender

The majority of the stroke patients with infarction was female (56.5%) and the rest was male. Similarly, Fauziah et al. (2012) found that ischemic stroke patients at Haji Adam Malik Hospital, Medan, were female (57.3%) and the

rest was male. This number, however, was only a variation of characteristics in each hospital.<sup>11</sup>

c. By comorbid

Patients with acute infarct stroke had the comorbid diseases, such as Hypertension (45.7%) and Diabetes Mellitus (34.8%). This result was in accordance with the theory that the incidence of acute infarct stroke was followed by metabolic syndrome as a comorbid disease. Similarly, Fauziah et al. (2012) found that the highest risk factor was hypertension (38.5%) and the lowest was smoking habit (3.4%).<sup>11</sup>

**ASL overview**

ASL sequences differed from each other regarding the changes in tagging segments, inflows, and reading sequences. The purpose of the tagging segment was to label

the incoming blood flow and the possible presence of blood closed to the brain. Initially, ASL was seen as an unsuitable technique for describing acute ischemic stroke. Its signal was disproportionate to cerebral blood flow (CBF), which was decreased in major vascular ischemic stroke. Furthermore, the remaining CBF was supplied by collateral flow that led to a longer arterial arrival time. The results of the present study were the fact that, 21 people's ASL picture was relatively normal. Such phenomena happened because there was stenosis of small blood vessels that became branches of large blood vessels. It could also be caused by stenosis that was categorized as mild and could also be caused by reperfusion of acute stroke lesions, of which the condition occurred either spontaneously or after successful intravenous or endovascular treatment.

This was in relevance to Zacharchuck (2014) that there were other artifacts to be aware of in the overall slow arterial flow to the brain, sometimes found in older patients or patients with poor cardiac output. In this case, ASL signal was seen only in the large arterial structures. As many as 25 people (54.3%) involved in the present study experienced a decrease in cerebral blood flow in ASL because stenosis occurred in large blood vessels. Moreover, stenosis occurred in several places, called multiple stenosis. Patients with acute ischemic stroke usually presented with a perfusion deficit (i.e., low to non-existent ASL CBF signal) in the affected area.<sup>7</sup> Chalela et al. (2000) conducted the first significant clinical study of the use of ASL in acute stroke. The investigators demonstrated the feasibility of using ASL and found an expected reduction in CBF in the affected area and demonstrated that CBF deficits correlated with the National Institutes of Health Stroke Scale.<sup>12</sup>

In coping with the present study, there was a pediatric patient aged 8 years (2.2%). This suggested that, although ischemic stroke was primarily an elderly's common disease, it might occur in children. Due to its rarity, a proper diagnosis was necessary to be undertaken. ASL was a promising technique in this patient population because of its higher baseline CBF and shorter arterial arrival time. Chen et al. (2009) described in their experience

evaluating pediatric ischemic stroke patients with ASL and demonstrating the concordance of the location and character of the perfusion deficit with clinical findings and diffusion-weighted imaging.<sup>13</sup> Particular interest was the possibility that ASL might be sensitive to preclinical episodes of ischemia in children with mitochondrial disease. Ikawa et al. (2013) demonstrated an abnormally high ASL signal in patients with MELAS syndrome (myopathy, encephalopathy, lactic acidosis, and stroke-like episodes) months before the clinical appearance of diffusion-positive stroke-like episodes.<sup>14</sup> This emphasized that ASL could be used for the management.

#### Limitations of Pit Fall ASL in Acute Stroke

Despite the high enthusiasm of the research community regarding ASL in acute stroke, there were limitations that should be reported. Although ASL had various interesting properties, it was a signal to noise ratio (SNR) technique that was lower than dynamic susceptibility contrast (DSC). There were several typical failures in ASL, one of which was an artifact that appeared as a decrease in CBF in a vascular territory that did not reflect a true decrease in flow, but a decrease in water labeling efficiency in a specific artery in the labeling area of neck.

This artifact was specific for continuous and pseudo continuous ASL. Although it was less familiar, it might present confusion in acute stroke since territorial infarcts could present similar findings. Movement artifacts also affected ASL on MRI where recent ASL sequences were more sensitive to movement within a certain range. Several methods could be used to deal with movement artifacts in ASL. One of them was by removing raw images that had movement before signal averaging. This could be done, however, could reduce the SNR of the final perfusion image. Another approach was the use of prospective movement correction, where the navigator's image followed the head directly and was used to follow the movement of the head during shooting process.<sup>7</sup>

#### Advantages of ASL

In 2012, three extensive studies compared ASL perfusion with DSC, a gadolinium-based technique that became the standard for measuring cerebral perfusion. These studies had mostly concordant findings and suggested that ASL could be used instead of DSC without any change in interpretation or subsequent clinical change. It was, therefore, important to understand the MRI features of acute stroke.<sup>7</sup>

#### MRA Overview

The results of the present study showed 10 people (21.7%) were normal and the rests (78.3%) had stenosis. This could be due to mild stenosis or stenosis in the distal arteries. Moreover, TOF MRA had limitations in visualization because the vascular signal depended on the direction of flow and velocity through the imaging field. Therefore, distal veins might not be accurately displayed.

Ischemic stroke was caused by a decrease in cerebral blood flow. This was because most of them (more than 80%) experienced atherosclerosis of large arteries or cardiac embolism (stroke thromboembolism). In regard to the present study, MRA images with mild stenosis or stenosis of small vessels were obtained in 28 out of 46 patients. Moderate to severe stenosis or occlusion of the great vessels was obtained in 8 patients and appeared normally in 10 patients. This was in connection with the theory that the most common cause of acute ischemic stroke was small vessel occlusion.

#### Advantages of MRA

36 patients (78.3%) from 46 samples, the results of MRA examination appeared to be stenosis due to the visual imaging that showed the presence of stenosis, the presence of mild stenosis, or severe or occlusion. Barlinn et al. (2011) stated that one of the advantages of TOF-MRA was that it did not require injection of contrast media and was an alternative for patients who were unable to receive contrast. In a comparative analysis with CE MRA, it was stated that the spatial resolution of TOF-MRA was superior to that of CE-MRA

(especially 3-order TOF dimensions). The volume covered was limited by vascular saturation artifacts, so TOF MRA was a more suitable technique for evaluating intracranial blood vessels in cases of cerebrovascular disease.<sup>10</sup>

#### Limitations of MRA

The present study found that 10 patients' (21.7%) MRA results were considered normal because the vascular signal in the MRA technique depended on the direction of blood flow and velocity through the imaging plane. Moreover, the mild stenosis in small blood vessels quickly got help from the surrounding blood vessels (collateral flow) so that visual imaging was not very visible because they were reperused. TOF-MRA tended to overestimate the degree, as well as the length of the stenosis (especially in the presence of turbulence, slow blood flow, or reverse circulation). Therefore, distal veins might not be accurately displayed. Nevertheless, TOF-MRA had an acceptable standard of sensitivity for steno-occlusive imaging of intracranial lesions compared to digital subtraction angiography (DSA) and computed tomographic angiography (CTA).

#### Research Limitations

In connection with the present study, the measurement of the results of MRA and ASL examinations was qualitative, therefore, an assessment was carried out by 2 Radiology Specialists. The statistical tests were carried out if there were a big difference and a low reliability.

#### CONCLUSION

There is a strong relationship between the results of magnetic resonance angiography examination with the results of the relative examination of cerebral blood flow on ASL in cases of acute ischemic stroke based on the results of the analysis with the p value. Further research is suggested to analyze blood vessels on MRI-MRA examination and quantitatively determine cerebral blood flow on ASL, especially in acute ischemic stroke patients with small infarct size and visually (qualitatively) relative normal.

## FUNDING

The authors are responsible for all of the study funding without a grant or any external funding source.

## CONFLICT OF INTEREST

No potential conflict of interest relevant to this article was reported.

## AUTHOR CONTRIBUTION

All authors similarly contribute to the think about from the investigate concepts, information acquisitions, information investigation, factual investigations, changing the paper, until detailing the consider comes about through publication.

## ETHICAL CONSIDERATION

Researchers applied to the ethics commission of PHC Surabaya Hospital by giving a research proposal before conducting the research at PHC Hospital. The research was undertaken after the ethical feasibility test was completed with certificate number 082/EC/KEPK/UNUSA/2021.

## ACKNOWLEDGMENTS

Thank you to UNICEF and Nahdlatul Ulama University Surabaya (UNUSA) for supporting the funding of this study.

## REFERENCES

- Vilela P, Rowley HA. Brain ischemia: CT and MRI techniques in acute ischemic stroke. *Eur J Radiol*. 2017 Nov;96:162–72.
- Aracki-Trenkic A, Law-Ye B, Radovanovic Z, Stojanov D, Dormont D, Pyatigorskaya N. ASL perfusion in acute ischemic stroke: The value of CBF in outcome prediction. *Clin Neurol Neurosurg*. 2020 Jul;194:105908.
- Kissela BM, Khoury JC, Alwell K, Moomaw CJ, Woo D, Adeoye O, et al. Age at stroke: temporal trends in stroke incidence in a large, biracial population. *Neurology*. 2012 Oct;79(17):1781–7.
- Hadley DM, Teasdale GM. Magnetic resonance imaging of the brain and spine. *J Neurol*. 1988 Mar;235(4):193–206.
- Watson CG, Dehaes M, Gagoski BA, Grant PE, Rivkin MJ. Arterial Spin Labeling Perfusion Magnetic Resonance Imaging Performed in Acute Perinatal Stroke Reveals Hyperperfusion Associated With Ischemic Injury. *Stroke*. 2016 Jun;47(6):1514–9.
- Grade M, Hernandez Tamames JA, Pizzini FB, Achten E, Golay X, Smits M. A neuroradiologist's guide to arterial spin labeling MRI in clinical practice. *Neuroradiology*. 2015 Dec;57(12):1181–202.
- Zaharchuk G. Arterial spin label imaging of acute ischemic stroke and transient ischemic attack. *Neuroimaging Clin N Am* [Internet]. 2011;21(2):285–301. x. Available from: <http://europepmc.org/abstract/MED/21640300>
- Belani P, Kihira S, Pacheco F, Pawha P, Cruciatu G, Nael K. Addition of arterial spin-labelled MR perfusion to conventional brain MRI: clinical experience in a retrospective cohort study. *BMJ Open*. 2020;10.
- Latchaw RE, Alberts MJ, Lev MH, Connors JJ, Harbaugh RE, Higashida RT, et al. Recommendations for imaging of acute ischemic stroke: a scientific statement from the American Heart Association. *Stroke*. 2009 Nov;40(11):3646–78.
- Barlinn K, Alexandrov A V. Vascular Imaging in Stroke: Comparative Analysis. *Neurotherapeutics*. 2011;8:340–8.
- Simargolang Jemadi, Hiswani IF. Karakteristik Penderita Stroke Iskemik dengan Infark yang Rawat Inap di RSUP Haji Adam Malik Medan Tahun 2012. *Gizi, Kesehatan Reproduksi dan Epidemiol* [Internet]. 2014;(Vol 1, No 2 (2014): Gizi, Kesehatan Reproduksi dan Epidemiologi). Available from: <http://jurnal.usu.ac.id/index.php/gkre/article/view/6534>
- Chalela JA, Alsop DC, Gonzalez-Atavales JB, Maldjian JA, Kasner SE, Detre JA. Magnetic resonance perfusion imaging in acute ischemic stroke using continuous arterial spin labeling. *Stroke*. 2000 Mar;31(3):680–7.
- Chen J, Licht DJ, Smith SE, Agner SC, Mason S, Wang S, et al. Arterial spin labeling perfusion MRI in pediatric arterial ischemic stroke: initial experiences. *J Magn Reson Imaging*. 2009 Feb;29(2):282–90.
- Ikawa M, Yoneda M, Muramatsu T, Matsunaga A, Tsujikawa T, Yamamoto T, et al. Detection of preclinically latent hyperperfusion due to stroke-like episodes by arterial spin-labeling perfusion MRI in MELAS patients. *Mitochondrion*. 2013 Nov;13(6):676–80.



This work is licensed under a Creative Commons Attribution



# Correlation of magnetic

---

## ORIGINALITY REPORT

---

**13%**

SIMILARITY INDEX

**9%**

INTERNET SOURCES

**9%**

PUBLICATIONS

**6%**

STUDENT PAPERS

---

## MATCH ALL SOURCES (ONLY SELECTED SOURCE PRINTED)

---

3%

★ Submitted to Universitas Airlangga

Student Paper

---

Exclude quotes  On

Exclude matches  < 1%

Exclude bibliography  On